



CMHD Pathology Report



CMHD Pathology Core

Toronto Centre for
Phenogenomics
25 Orde St. 3rd fl.
Toronto, Ont. M5T 3H7
Tel.(416) 586-8375
Fax (416) 586-5993

contact: Dr. Susan
Newbigging
email:
newbigging@lunenfeld.ca

ReportID: Report Date: January 28, 2014
Pathologist: Dr. H. Adissu

Mouse Genetics Project

Wellcome Trust Sanger
Institute
Wellcome Trust Genome
Campus
Hinxton, Cambridge
CB10 1SA
UK

CMHD LabID: N13-910

Relevant History:

Phenotypes:

MP:0010053 decreased grip strength
MP:0002968 increased circulating alkaline phosphatase level
MP:0005478 decreased circulating thyroxine level
MP:0000194 hypercalcemia
MP:0000221 decreased leukocyte cell number
MP:0005017 decreased B cell number
MP:0000322 increased granulocyte number
MP:0004973 increased regulatory T cell number

AnimalID: M00981439 (Male)

Histopathology Findings:

spleen (MA:0000141)

Histopath Description:

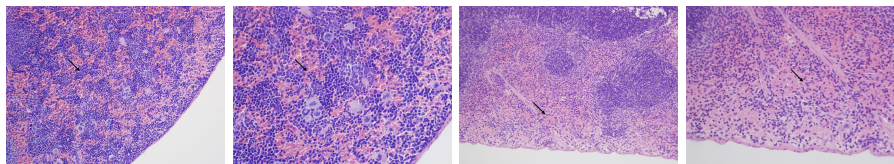
There is marked erythroid and moderate granulocytic and megagaryocytic hyperplasia

Morphological Diagnosis:

Distribution: multifocal to coalescing; **Severity:** moderate; **MPATH Diagnosis:** extramedullary hemopoiesis MPATH:595; **MPATH Process Term:** hyperplasia MPATH:134

Definitive Diagnosis:

Trilineage extramedullary hematopoiesis - moderate to marked



Spleen, Trilineage
extramedullary
hematopoiesis ,
20x, HE

Spleen, Trilineage
extramedullary
hematopoiesis ,
40x, HE

Spleen, wildtype,
normal, 20x, HE.

Spleen, wildtype,
normal, 40x, HE.

bone marrow (MA:0000134)

Histopath Description:

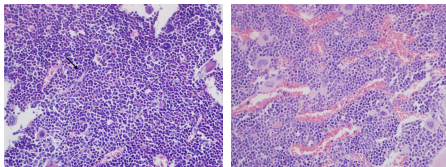
Moderate granulocytic hyperplasia

Morphological Diagnosis:

Distribution: diffuse; **Severity:** moderate; **MPATH Process Term:** hyperplasia MPATH:134

Definitive Diagnosis:

Granulocytic hyperplasia



Bone marrow,
granulocytic
hyperplasia, 40x,
HE

Bone marrow,
wildtype, normal,
40x, HE

Lymph node (MA:0000139)

Histopath Description:

The mesenteric lymph node is markedly enlarged (greater than four fold). The medulla is particularly expanded by chords and sheets of plasmotoid cells. There are prominent germinal centers within the medulla

Morphological Diagnosis:

Distribution: Diffuse; **Severity:** moderate; **MPATH Diagnosis:** hyperplasia MPATH:134;
MPATH Process Term: hyperplasia MPATH:134

Definitive Diagnosis:

Lymphoid hyperplasia

Histopathology Comments:

The changes in the mesenteric lymph node are suggestive of draining of a regional inflammatory process. However, such a process was not observed in the tissues examined. Early marginal center lymphoma is suspected.

Lymph node (MA:0000139)

Histopath Description:

Lymphoid hyperplasia with marked sinus plasmacytosis

Morphological Diagnosis:

Distribution: diffuse; **Severity:** severe; **MPATH Process Term:** hyperplasia MPATH:134

Definitive Diagnosis:

Lymphoid hyperplasia with sinus plasmacytosis

Organ/Tissue Analyzed:

Histopathology examination included the following organs and tissues: brain, trigeminal ganglion, eyes, salivary glands, trachea, lungs, heart, thymus, thyroid gland, parathyroid gland, exocrine and endocrine pancreas, oesophagus, stomach, small intestine, large intestine, liver, gall bladder, spleen, kidneys, adrenal gland, lymph nodes, spinal cord, bone marrow, sternum, femur and tibia with associated skeletal muscles, brown fat, pinna, skin, testis, epididymis, seminal vesicle, and prostate.

AnimalID: M01030001 (Male)

Histopathology Findings:

spleen (MA:0000141)

Histopath Description:

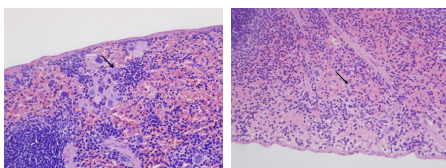
Mild megakaryocyte hyperplasia

Morphological Diagnosis:

Distribution: multifocal; **Severity:** mild; **MPATH Diagnosis:** extramedullary hemopoiesis MPATH:595; **MPATH Process Term:** hyperplasia MPATH:134

Definitive Diagnosis:

Megakaryocytic hyperplasia



Spleen,
Megakaryocytic
hyperplasia, 40x,
HE.

Spleen, wildtype,
normal, 40x, HE.

Organ/Tissue Analyzed:

Histopathology examination included the following organs and tissues: brain, trigeminal ganglion, eyes, salivary glands, trachea, lungs, heart, thymus, thyroid gland, parathyroid gland, exocrine and endocrine pancreas, oesophagus, stomach, small intestine, large intestine, liver, gall bladder, spleen, kidneys, adrenal gland, lymph nodes, spinal cord, bone marrow, sternum, femur and tibia with associated skeletal muscles, brown fat, pinna, skin, testis, epididymis, seminal vesicle, and prostate.

AnimalID: M00981432 (Female)

Histopathology Findings:

spleen (MA:0000141)

Histopath Description:

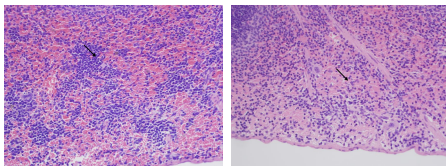
Mild erythroid hyperplasia

Morphological Diagnosis:

Distribution: multifocal; **Severity:** mild; **MPATH Diagnosis:** extramedullary hemopoiesis MPATH:595; **MPATH Process Term:** hyperplasia MPATH:134

Definitive Diagnosis:

Erythroid hyperplasia



Spleen, Erythroid hyperplasia, 40x, HE

Spleen, wildtype, normal, 40x, HE.

Organ/Tissue Analyzed:

Histopathology examination included the following organs and tissues: brain, trigeminal ganglion, eyes, salivary glands, trachea, lungs, heart, thymus, thyroid gland, parathyroid gland, exocrine and endocrine pancreas, oesophagus, stomach, small intestine, large intestine, liver, gall bladder, spleen, kidneys, adrenal gland, lymph nodes, spinal cord, bone marrow, sternum, femur and tibia with associated skeletal muscles, brown fat, pinna, skin, uterus, oviduct, and ovary, and mammary gland.

AnimalID: M00981431 (Female)

Histopathology Findings:

spleen (MA:0000141)

Histopath Description:

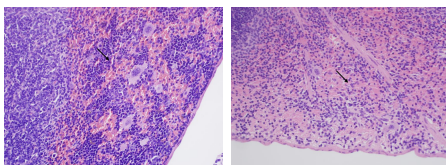
There is marked erythroid and moderate granulocytic and megagaryocytic hyperplasia

Morphological Diagnosis:

Distribution: multifocal to coalescing; **Severity:** moderate; **MPATH Diagnosis:** extramedullary hemopoiesis MPATH:595; **MPATH Process Term:** hyperplasia MPATH:134

Definitive Diagnosis:

Trilineage extramedullary hematopoiesis - moderate to marked



Spleen, Trilineage extramedullary hematopoiesis , 40x, HE

Spleen, wildtype, normal, 40x, HE.

Organ/Tissue Analyzed:

Histopathology examination included the following organs and tissues: brain, trigeminal ganglion, eyes, salivary glands, trachea, lungs, heart, thymus, thyroid gland, parathyroid gland, exocrine and endocrine pancreas, oesophagus, stomach, small intestine, large intestine, liver, gall bladder, spleen, kidneys, adrenal gland, lymph nodes, spinal cord, bone marrow, sternum, femur and tibia with associated skeletal muscles, brown fat, pinna, skin, uterus, oviduct, and ovary, and mammary gland.

Report Summary and Recommendation:

Mian findings in this line are mild to moderate increase in splenic hematopoietic population (extramedullary

hematopoiesis) in all mice and a corresponding bonemarrow granulocytic hyperplasia in one mouse. These changes may explain the increased granulocyte number observed in this line. Hyperplasia of the mesenteric and inguinal lymph nodes was observed in one mouse. Lymph node hyperplasia could also be seen in wildtype mice albeit at low prevalence (5-15% in various B6 WT strains we have analyzed). Hence this finding should be interpreted with caution. We did not find morphological explanation for most of the phenotypes (decreased grip strength, increased circulating alkaline phosphatase level, decreased circulating thyroxine level, hypercalcemia, decreased leukocyte cell number, decreased B cell number).

Summary: Spleen: Erythroid hyperplasia (4/4); megakaryocyte hyperplasia (3/4); granulocytic hyperplasia (2/4).