



CMHD Pathology Report



CMHD Pathology Core

Toronto Centre for
Phenogenomics
25 Orde St. 3rd fl.
Toronto, Ont. M5T 3H7
Tel.(416) 586-8375
Fax (416) 586-5993

contact: Dr. Susan
Newbigging
email:
newbigging@lunenfeld.ca

ReportID: Report Date: January 10, 2014
Pathologist: Dr. H. Adissu

Mouse Genetics Project

Wellcome Trust Sanger
Institute
Wellcome Trust Genome
Campus
Hinxton, Cambridge
CB10 1SA
UK

CMHD LabID: N13-715

Relevant History:

increased bone mineral density
abnormal retinal pigmentation
decreased circulating fructosamine level
Homozygous partial lethality
Homozygous embryonic death during fetal growth and development

AnimalID: M01074990 (Male)

Histopathology Findings:

retina (MA:0000276)

Histopath Description:

There are clusters of external nuclear structures within the layer of rods and cons. There is segmental choroid hyperplasia (red arrow).

Morphological Diagnosis:

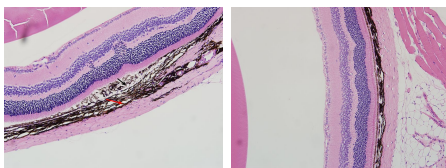
Distribution: multifocal; **Severity:** mild; **MPATH Diagnosis:** developmental and structural abnormality MPATH:55; **MPATH Process Term:** developmental and structural abnormality MPATH:55

Definitive Diagnosis:

Retinal dysplasia

Histopathology Comments:

Retinal dysplasia is reported as a background lesion in C57BL/6N lines (Mattapallil et al., 2012).



Retina, dysplasia (arrow) and choroid hyperplasia (red arrow), 20x, HE Retina, WT, normal, 20x, HE

skin (MA:0000151)

Histopath Description:

There are focal aggregate of neutrophils admixed with nuclear debris attached to the epidermis of the pinna and the back (scabs).

Morphological Diagnosis:

Distribution: multifocal; **Severity:** mild; **MPATH Diagnosis:** inflammation MPATH:212; **MPATH Process Term:** inflammation MPATH:212

Definitive Diagnosis:

Epidermitis, multifocal

Histopathology Comments:

This is considered an incidental lesion likely caused by focal trauma. Also note that some strains of B6 mouse develop idiopathic dermatitis

brain (MA:0000168)**Histopath Description:**

There is mild dilation of the fourth ventricle

Morphological Diagnosis:

Severity: mild; **MPATH Process Term:** degenerative change MPATH:14

Definitive Diagnosis:

Dilation of the brain ventricles

Histopathology Comments:

Mild dilation of the ventricles is a background condition in mice of C57BL/6N background

thymus (MA:0000142)**Histopath Description:**

There are two 50 um diameter epithelial cysts.

Morphological Diagnosis:

Distribution: multifocal; **MPATH Diagnosis:** cyst MPATH:62; **MPATH Process Term:** developmental and structural abnormality MPATH:55

Definitive Diagnosis:

Epithelial cyst

Histopathology Comments:

This is a developmental abnormality commonly seen in mice.

Organ/Tissue Analyzed:

Histopathology examination included the following organs and tissues: brain, trigeminal ganglion, eyes, salivary glands, trachea, lungs, heart, thymus, thyroid gland, parathyroid gland, exocrine and endocrine pancreas, oesophagus, stomach, small intestine, large intestine, liver, gall bladder, spleen, kidneys, adrenal gland, lymph nodes, spinal cord, bone marrow, sternum, femur and tibia with associated skeletal muscles, brown fat, pinna, skin, testis, epididymis, seminal vesicle, and prostate.

AnimalID: M01074989 (Male)**Histopathology Findings:****retina (MA:0000276)****Histopath Description:**

There is a focal retinal fold at the posterior aspect.

Morphological Diagnosis:

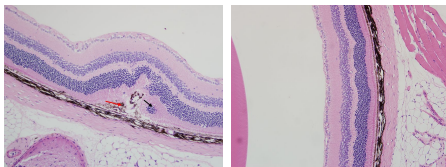
Distribution: multifocal; **Severity:** mild; **MPATH Process Term:** developmental and structural abnormality MPATH:55

Definitive Diagnosis:

Retinal dysplasia

Histopathology Comments:

Retinal dysplasia is reported as a background lesion in C57BL/6N lines (Mattapallil et al., 2012).



Retina,
dysplasia/retinal
fold, 20x, HE

Retina, WT, normal,
20x, HE

Organ/Tissue Analyzed:

Histopathology examination included the following organs and tissues: brain, trigeminal ganglion, eyes, salivary glands, trachea, lungs, heart, thymus, thyroid gland, parathyroid gland, exocrine and endocrine pancreas, oesophagus, stomach, small intestine, large intestine, liver, gall bladder, spleen, kidneys, adrenal gland, lymph nodes, spinal cord, bone marrow, sternum, femur and tibia with associated skeletal muscles, brown fat, pinna, skin, testis, epididymis, seminal vesicle, and prostate.

AnimalID: M01076004 (Female)**Histopathology Findings:**

retina (MA:000276)**Histopath Description:**

There are clusters of external nuclear structures within the layer of rods and cons.

Morphological Diagnosis:

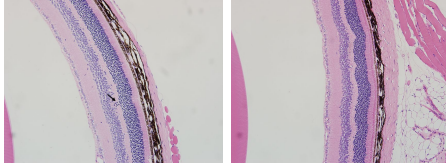
Distribution: multifocal; **Severity:** mild; **MPATH Diagnosis:** developmental and structural abnormality MPATH:55; **MPATH Process Term:** developmental and structural abnormality MPATH:55

Definitive Diagnosis:

Retinal dysplasia

Histopathology Comments:

Retinal dysplasia is reported as a background lesion in C57BL/6N lines (Mattapallil et al., 2012).



Retina, dysplasia,
20x, HE

Retina, WT, normal,
20x, HE

Organ/Tissue Analyzed:

Histopathology examination included the following organs and tissues: brain, trigeminal ganglion, eyes, salivary glands, trachea, lungs, heart, thymus, thyroid gland, parathyroid gland, exocrine and endocrine pancreas, oesophagus, stomach, small intestine, large intestine, liver, gall bladder, spleen, kidneys, adrenal gland, lymph nodes, spinal cord, bone marrow, sternum, femur and tibia with associated skeletal muscles, brown fat, pinna, skin, uterus, oviduct, and ovary, and mammary gland.

AnimalID: M01083544 (Female)**Histopathology Findings:****retina (MA:000276)****Histopath Description:**

There are clusters of external nuclear structures within the layer of rods and cons.

Morphological Diagnosis:

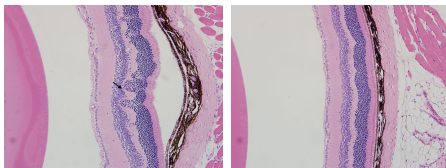
Distribution: multifocal; **Severity:** mild; **MPATH Diagnosis:** developmental and structural abnormality MPATH:55; **MPATH Process Term:** developmental and structural abnormality MPATH:55

Definitive Diagnosis:

Retinal dysplasia

Histopathology Comments:

Retinal dysplasia is reported as a background lesion in C57BL/6N lines (Mattapallil et al., 2012).



Retina, dysplasia,
20x, HE

Retina, WT, normal,
20x, HE

knee (MA:000046)**Histopath Description:**

Moderate numbers of macrophages and lymphocytes and rare granulocytes are present within the periarticular tissue

Morphological Diagnosis:

Duration: chronic-active; **Distribution:** multifocal to coalescing; **Severity:** moderate; **MPATH Process Term:** inflammation MPATH:212

Definitive Diagnosis:

Periarthritis of the knee joint

lymph node (MA:000139)**Histopath Description:**

The mesenteric lymph node is markedly enlarged (greater than four fold). The medulla is particularly expanded by chords and sheets of plasmotoid cells. There are prominent germinal centers within the medulla

Morphological Diagnosis:

Distribution: Diffuse; **Severity:** moderate; **MPATH Diagnosis:** hyperplasia MPATH:134;
MPATH Process Term: hyperplasia MPATH:134

Definitive Diagnosis:

Lymphoid hyperplasia

Histopathology Comments:

The changes in the mesenteric lymph node are suggestive of draining of a regional inflammatory process. However, such a process was not observed in the tissues examined. Early maginal center lymphoma is suspected.

Organ/Tissue Analyzed:

Histopathology examination included the following organs and tissues: brain, trigeminal ganglion, eyes, salivary glands, trachea, lungs, heart, thymus, thyroid gland, parathyroid gland, exocrine and endocrine pancreas, oesophagus, stomach, small intestine, large intestine, liver, gall bladder, spleen, kidneys, adrenal gland, lymph nodes, spinal cord, bone marrow, sternum, femur and tibia with associated skeletal muscles, brown fat, pinna, skin, uterus, oviduct, and ovary, and mammary gland.

Report Summary and Recommendation:

Mild dysplastic retinal lesions are present in three mice. The lesion may explain the abnormal retinal pigmentation/morphology documnted during clinical phenotyping. However, this finding should be cautiously interpreted in light of the high prevalence of similar lesions in this strain (C57BL/6N). Other lesions are considered incidental. No morphological abnormalities were found to explain increased bone mineral density, decreased circulating fructosamine level.

Line summary:

Eye - retinal dysplasia (4/4); choroid hyperplasia (1/4)